

17. Bellon G, Caulet T, Cam Y, Pluot M, Poulin G, Pytlinska M and Bernard MH: Immunohistochemical localisation of macromolecules of the basement membrane and extracellular matrix of human gliomas and meningiomas. *Acta Neuropathol* 66: 245-252, 1985.
18. Rutka JT, Myatt CA, Giblin JR, Davis RL and Rosenblum ML: Distribution of extracellular matrix proteins in primary human brain tumours: an immunohistochemical analysis. *Can J Neurol Sci* 14: 25-30, 1987.
19. Nitta H, Yamashita T, Yamashita J and Kubota T: An ultrastructural and immunohistochemical study of extracellular matrix in meningiomas. *Histol Histopathol* 5: 267-274, 1990.
20. Kilic T, Bayri Y, Ozduman K, Acar M, Diren S, Kurtkaya O, Ekinci G, Bugra K, Sav A, Ozek MM and Pamir MN: Tenascin in meningiomas: expression is correlated with anaplasia, vascular endothelial growth factor expression, and peritumoral edema but not with tumour border shape. *Neurosurgery* 51: 183-192, 2002.
21. Rooprai HK, van Meter T, Rucklidge, GJ, Hudson L, Everall IP, and Pilkington GJ: Comparative analysis of matrix metalloproteinases by immunocytochemistry, immunohistochemistry and zymography in human primary brain tumours. *Int J Oncol* 13: 1153-1157, 1998.
22. Rooprai HK, Liyanage K, Robinson SFD, Kandaneeratchi A, Dean AF and Pilkington GJ: Extracellular matrix-modulated differential invasion of human meningioma cell lines *in vitro*. *Neurosci Lett* 263: 214-216, 1999.
23. Perry A, Scheithauer BW, Stafford SL, Lohse CM and Wollan PC: 'Malignancy' in meningiomas. A clinicopathological study of 116 patients, with grading implications. *Cancer* 85: 2046-2056, 1999.

Expression of MMP-2 and -9 in short-term cultures of meningioma: Influence of histological subtype

HARCHARAN K. ROOPRAI¹, TIMOTHY E. VAN METER², SUSAN D.F. ROBINSON³,
ANDREW KING³, GARRY J. RUCKLIDGE⁴ and GEOFFREY J. PILKINGTON¹

¹School of Pharmacy and Biomedical Sciences, University of Portsmouth, St. Michael's Building, White Swan Road, Portsmouth, PO1 2DT, UK; ²Division of Neurosurgery, Medical College of Virginia, Virginia Commonwealth University, Richmond, VA, USA; ³Department of Neuropathology, Institute of Psychiatry, King's College London, De Crespigny Park, London, SE5 8AF; ⁴Department of Biochemistry, The Rowett Research Institute, Greenburn Road, Bucksburn, Aberdeen, AB2 9SB, Scotland, UK

Received June 23, 2003; Accepted July 24, 2003

Abstract. Matrix metalloproteinases (MMPs) belong to a super family of endopeptidases which have been implicated as crucial mediators of angiogenesis and tumour invasion in brain tumours. This study was undertaken in an attempt to establish the relationship between 2 specific MMPs and the main classical subtypes of meningioma. We examined the expression of MMP-2 and -9 (gelatinase-A and -B respectively), by gelatin zymography, in a series of 18 cell cultures derived from human meningiomas of a range of histological subtypes and grades of malignancy, including 7 meningothelial, 6 transitional, 2 fibroblastic and 3 atypical meningiomas. Our findings indicate that generally, the meningothelial subtype, had the weakest expression, the transitional subtype had an intermediate expression whereas the fibroblastic subtype had the strongest expression of both MMP-2 and -9. There was no correlation between other clinicopathological features (age, sex, site of tumour) and the level of MMP-2 and -9 expression. Although, the number of samples in this study is limited, these findings suggest that there may be a trend for association between the expression of these 2 MMPs and the main classical histological subtypes of meningioma.

Introduction

Meningiomas are thought to constitute approximately 20% of primary intracranial neoplasms, with an annual incidence of approximately 6 per 100,000 (1). Atypical meningiomas constitute approximately 6% of meningiomas. These are meningeal tumours that tend to behave in a more aggressive

fashion than classical meningiomas (usually an increased risk of recurrence) but lack unequivocal malignant features. Histopathologically they tend to have an increased mitotic rate and/or a collection of other features including necrosis, cellular sheeting, pleomorphism and prominent nucleoli. Although these neoplasms can occur in children, they are most common in middle-aged and elderly patients, with a peak in occurrence during the sixth and seventh decade of life. They also demonstrate a female preponderance.

The World Health Organization (WHO) classification of meningiomas recognises a variety of histological subtypes, the most common ones being the classical subtypes: meningothelial, fibroblastic and transitional. All meningiomas are divided into three grades ranging from benign to malignant (1). Arising from arachnoidal cells of the leptomeninges, meningiomas display a wide range of morphological appearances. In meningothelial meningioma, neoplastic cells form lobules which are surrounded by thin collagenous septa. A typical histological feature of this subtype is intranuclear inclusions. Transitional (mixed) meningioma has features transitional between meningothelial and fibroblastic subtypes. Typically, they appear to have numerous, concentric, onion-bulb structures. In the fibroblastic (fibrous) subtype, the tumour cells are commonly spindle-shaped and there is often a dense matrix of collagen (1). The meningothelial subtype, in contrast, tends to contain little collagen but often has a lobular syncytial pattern of cells. The transitional meningioma by definition tends to have a pattern that falls between these 2 extremes and is also intermediate in the quantity of collagen in the matrix. Atypical meningiomas are more morphologically heterogeneous as a group and can have underlying patterns that resemble fibroblastic, meningothelial or transitional types but they are defined by other criteria as described above.

In an attempt to better define the molecular basis of these subtypes, recent work in the field has concentrated on cell adhesion molecules, growth factors and cytokines as well as other tumour-related genes and proteins (2,3). Meningiomas, like gliomas, are highly vascularised solid tumours. Tumour invasion and angiogenesis require controlled degradation of

Correspondence to: Dr H.K. Rooprai, School of Pharmacy and Biomedical Sciences, University of Portsmouth, St. Michael's Building, White Swan Road, Portsmouth, PO1 2DT, UK

Key words: meningiomas, metalloproteinases, collagen

the extracellular matrix (ECM) to permit either neoplastic or endothelial cell migration and its restructuring. Widespread interest in recent years has led to the examination of the role of protease families including serine-, cysteine-, and matrix metalloproteinases (MMPs), as critical players in neoplastic expansion, tumour cell migration and angiogenesis.

To date, 25 MMPs have been identified (4). These enzymes are divided into different subclasses, based on their substrate specificity, protein domain and sequence homology. Of these, four members belong to the collagenase subclass, including MMP-1, -8, -13 and -18; two belong to the gelatinase subclass (MMP-2 and -9); five belong to the stromelysin subclass (MMP-3, -7, -10, -11 and -26) and six are membrane-type MMPs (MMP-14, -15, -16, -17, -24 and -25). Some of the very recently identified members may form new subclasses, as they lack conserved protein domains found in other family members.

There are several conflicting reports on MMP expression in meningiomas in the literature. Some authors have studied meningiomas separately (5-8) whereas others have attempted to compare their MMP expression, often as a group, with that of other brain neoplasms (9-14). The aim of this study is to ascertain whether there is a correlation between the expression of one subgroup of MMPs, the gelatinases, (MMP-2 and -9 or gelatinase-A and -B, respectively) and short-term low passage cultures of meningothelial, fibrous, transitional and atypical meningiomas.

Materials and methods

Tissue specimens and cell culture. Surgical samples from 17 patients with meningiomas were obtained from the neurosurgical staff of King's College Hospital, London. Mr K. O'Neil from Atkinson Morley's Hospital, London, kindly provided one sample (AMH-PP) for this study. At the time of neurosurgery, patients (6 males and 12 females) were between the age of 30 and 81. All the samples analysed were diagnosed, according to the WHO criteria (1) by a neuropathologist (S.D.F.R.) and confirmed by a second neuropathologist (A.K.). They were subdivided into groups, based on tumour subtypes. The main clinicopathological data are summarised in Table I. There were 7 meningothelial, 2 fibrous, 6 transitional and 3 atypical meningiomas in the study.

Biopsy material obtained was used to establish short-term cell cultures. Cells were cultured as monolayers in small plastic culture flasks (Marathon) at 37°C and 5% CO₂ in a humidified atmosphere. Cells were initially maintained in Dulbecco's modified Eagle's medium (DMEM) supplemented with antibiotic/antimycotic (at the final concentration of 100 IU penicillin, 100 µg streptomycin and 25 µg amphotericin per ml) and 10% fetal bovine serum (Sigma). The meningioma cell cultures used in this study were at low passages (between 2 and 6).

Gelatin zymography. Gelatin zymogram analysis was performed for MMP-2 and -9 by a modification of the methods of Heussen and Dowdle (15) and Rucklidge *et al.* (16). Briefly, specimens were prepared by weaning near confluent (approximately 80%) monolayer meningioma cultures from 10% FCS to serum-free medium stepwise over 48 h. Serum-free media was collected and frozen at -80°C for zymogram

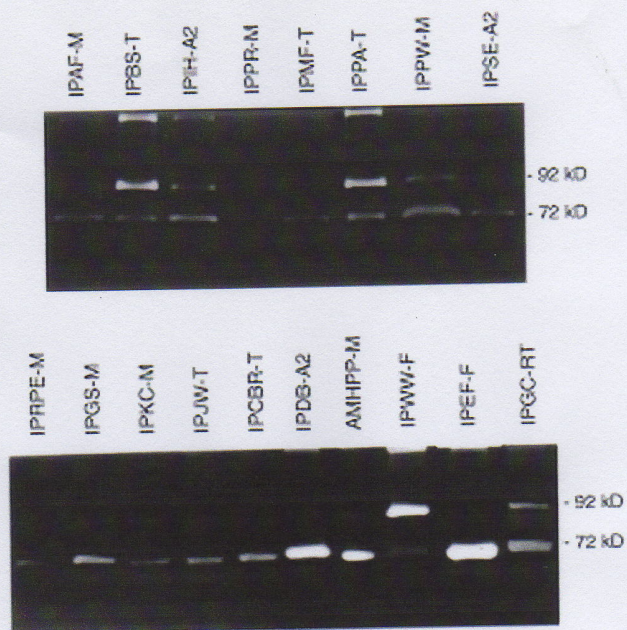


Figure 1. Gelatin zymogram of 18 human meningioma. All cell cultures studied (with one exception, IPRM-M) expressed MMP-2 (72 kDa), whereas, a third of them expressed MMP-9 (92 kDa). The intensity of the clear bands of the dark background is proportional to proteolytic activity.

analysis. Samples were dialysed against water for 16 h individually and freeze dried. The volumes for zymogram analysis were calculated on the basis of loading the equivalent of 4,800 cells' contribution to the medium, a rough estimate for detectable levels. Gelatin substrate was co-polymerized into an 11% acrylamide resolving gel at the time of gel casting. An aliquot (40 µl) of cell-conditioned medium was mixed with 15 µl of a loading buffer (Tris-base) containing 30% glycerol, 7.7% sodium dodecyl sulphate (SDS) and 0.3% bromophenol blue at pH 6.8 before being loaded into stacking gel wells. Following electrophoresis in a Mini Protean II Dual Slab Cell (Bio-Rad), the gels were immersed in Triton X-100 (2.5%) for 3 h to deactivate the enzymes within the gel by removing the SDS. The enzymes were then reactivated by incubating the gels in 50 mM Tris-HCl buffer (pH 7.6) containing 10 mM CaCl₂ at 37°C overnight. The gels were stained in 0.025% Coomassie blue in methanol:acetic acid:water (10:1:10 v:v:v) for 4 h. Finally, the gels were destained with methanol:acetic acid:water (2:1:10 v:v:v) for 24 h. Proteolytic activity appeared as clear bands on a dark blue background. The bands were identified by their molecular weights: 72 kDa and 92 kDa, corresponding to MMP-2 and -9, respectively. Proteolytic activity was evaluated using an IBAS 200 image analyser and verification of the MMP status of enzymes detected was achieved in control experiments by substituting the 10 mM CaCl₂ in the incubation buffer with a MMP inhibitor, 1,10-phenanthroline (0.5 mM final concentration).

Results

Fig. 1 represents results from the zymogram analysis of gelatinase-A (MMP-2) and -B (MMP-9) expression in 18 cell

Table I. Clinical data and histological classification of 18 human meningiomas used.

Cell line Designation	Age (years)	Sex	Tumour site	Tumour subtype	Tumour grade
IPGS (P3)	43	M	Frontal	Meningothelial	I
IPRPE (P6)	72	M	Spinal (thoracic)	Meningothelial	I
IPKC (P4)	37	F	Spinal (cervical)	Meningothelial	I
IPAF (P5)	65	F	Intracranial NOS	Meningothelial	I
IPPW (P2)	61	F	R pre-tous ridge	Meningothelial	I
IPPR (P3)	62	F	R fronto-parietal	Meningothelial	I
AMH-PP (P5)	50	F	Intracranial NOS	Meningothelial	I
IPCBR (P2)	58	F	R fronto-parietal	Transitional	I
IPJW (P2)	52	F	R parietal	Transitional	I
IPPA (P4)	45	F	Intracranial NOS	Transitional	I
IPBS (P3)	56	M	Intracranial NOS	Transitional	I
IPMF (P3)	60	F	L vault	Transitional	I
IPGC (P2)	68	M	Intracranial (recurrent)	Transitional	I
IPEF (P6)	61	F	R fronto-parietal	Fibrous	I
IPWW (P2)	75	M	L parietal	Fibrous	I
IPDB (P4)	80	F	L temporal	Atypical	II
IPIH (P4)	81	F	Intracranial NOS	Atypical	II
IPSE (P3)	30	M	Midline subfrontal	Atypical	II

Prefix IP, Institute of Psychiatry; AMH, Atkinson Morley's Hospital; R, right; L, left; NOS, not otherwise stated; P, passage number.

cultures derived from human meningiomas of a range of histological subtypes and grades of malignancy. The qualitative results showed the presence of both gelatinase-A and -B in meningiomas indicated by the clear bands corresponding to their molecular weights of 72 and 92 kDa, respectively. All the cell cultures studied, except one meningothelial meningioma (IPPR-M), expressed MMP-2. Although, 13/18 (72%) of the cell cultures showed low expression of MMP-2, particularly intense bands, corresponding to high expression of MMP, were observed in one atypical (IPDB-A2), one meningothelial (AMHPP-M), and one recurrent transitional meningioma (IPGC-RT). The most intense band for MMP-2 expression was seen in one of the two fibroblastic meningiomas in this study (IPEE-F) (Fig. 1).

MMP-9 was not generally co-expressed with MMP-2 in our samples, since it was only detected in 6/18 (33%) cell cultures. Weak expression of MMP-9 was seen in 3 cultures, a meningothelial meningioma (IPPW-M), a recurrent transitional meningioma (IPGC-RT) and an atypical meningioma (IPIH-A2). Strong expression of MMP-9 was detected in 2 transitional meningiomas (IPBS-T and IPPA-T) but the most intense MMP-9 expression was seen in the other fibroblastic meningioma (IPWW-F). However, MMP-2 and -9 were not mutually exclusive in the fibroblastic meningiomas as IPWW-F expressed the highest level of MMP-9 and a low level of MMP-2 whereas IPEF-F expressed the highest level of MMP-2 but no MMP-9. Moreover, there were no obvious correlations between clinico-pathological features, such as age,

sex or site of tumour (Table I) and MMP-2 and-9 expression in this study.

Discussion

In this study, we examined the relationship between gelatinase (MMP-2 and -9) expression by gelatin zymography in 7 meningothelial, 6 transitional, 2 fibroblastic and 3 atypical meningiomas. The results indicated that meningothelial subtype, generally, had the lowest expression of both MMPs, the transitional subtype had an intermediate expression whereas the fibroblastic subtype had the strongest expression of either MMP-2 or MMP-9. More specifically, our results found MMP-9 activity in 6 out of the 18 cell cultures tested in zymography (33%). The data indicated that the meningothelial subtype generally expressed MMP-9 to the least extent, 3/6 (50%) of the transitional subtype expressed it to a moderate level and the most pronounced expression was seen in one of the two fibroblastic subtype. Interestingly, one fibroblastic meningioma (IPEF-F) strongly expressed MMP-2 only while the other (IPWW-F) strongly expressed MMP-9 but weakly expressed MMP-2. Clearly, the expression of the MMPs in this subtype was not mutually exclusive.

Given that the collagen content of the meningothelial subtype is low, that of transitional subtype is intermediate whereas the fibroblastic subtype has high collagenous background, this study suggests that there may be a trend associating MMP expression and histological subtype of

classical meningioma. This finding may reflect the difference in ECM composition found *in vivo* in classical meningiomas as collagen type IV is a specific substrate for both MMP-2 and -9. In addition, we have previously suggested that MMPs may be produced locally on demand *in vivo*, in very small quantities (21).

Immunohistochemical analyses have led to the documentation of the ECM components of meningiomas (17-19). Such studies suggest that most histological subtypes of meningiomas contain collagens I, III, IV and VI, laminin and fibronectin. The expression of tenascin was reported to correlate with anaplasia, VEGF (vascular endothelial growth factor) expression and peritumoral oedema in a study including 20 classical, 20 atypical and 5 malignant meningiomas (20).

Our present data are not in agreement with that of Kirches and colleagues who evaluated the expression of MMP-2 and -9 in a series of 12 meningiomas (3 meningothelial, 3 fibroblastic, 4 transitional, 1 psammomatous and 1 atypical) using zymography and reverse-transcription PCR (RT-PCR) methods (8). As no gelatinase activity was detected in any of their samples, they suggested that neither of these MMPs play a major role in tumour growth with dura mater or brain invasion (8).

Cumulative data from our present study on MMP expression by zymography in meningiomas and our previous study in gliomas (21) are consistent with those of Kachra *et al.* (10) who have reported a study of 3 MMPs and 2 tissue inhibitors of MMPs (TIMPs) in 60 brain tumours. In their study, 9 meningiomas (grade 1, not subtyped) had similar patterns of MMP activity compared with gliomas, although the major MMP detected was MMP-9 whereas MMP-2 was the more prominent in both our meningiomas and gliomas.

Earlier reports of MMP expression in various grades of meningiomas have often suggested that they have a potential to infiltrate dura mater (6,7,10). The interpretation for the data for the 3 atypical meningiomas in our study is somewhat difficult as there is no clear pattern of expression of MMP. This is not altogether surprising since this is a rather heterogeneous group which depends on the bringing together of some very separate histological criteria for their inclusion into this grade.

In a related study, we have previously reported the extracellular matrix-modulated differential invasion of 6 human meningiomas (including 5 from the current study: IPGS-M, IPCBR-F, IPGC-RT, IPIH-A2 and IPSE-A2) *in vitro* (22). The IPSE-A2 meningioma had minimal expression of MMP-2 only, in the current study and was less invasive *in vitro* compared to the benign transitional IPCBR-T and the atypical meningioma, IPIH-A2 (22). The tumour from which the IPSE cell culture was derived from has now been reclassified from a malignant meningioma to an atypical meningioma following the stricter updated definitions in the WHO 2000 classification (1,23).

We can postulate that our findings may support the notion that MMP-2 and -9 expression reflects the histological subtype of meningioma. Further characterization studies focusing on other MMPs are needed to elucidate more fully the role of these proteases in meningiomas. Ongoing research in our laboratories is focusing on gene expression of various MMPs and their inhibitors (TIMPs) in a larger number of

meningiomas as well as immunohistochemical studies on invasive meningiomas, with a battery of MMP antibodies, to ascertain if there is a positive correlation between MMP expression and different subtypes of classical meningiomas.

Acknowledgements

The authors are grateful to the Association for International Cancer Research and the British Brain Tumour Association for their financial support of this study.

References

1. Kleihues P and Cavenee WK (eds): Pathology and Genetics of Tumours of the Nervous System. Pub IARC Press, Lyon, 2000.
2. Figarella-Branger D, Roche PH, Daniel L, Dufour H, Bianco N and Pellissier JF: Cell-adhesion molecules in human meningiomas: correlation with clinical and morphological data. *Neuropathol Appl Neurobiol* 23: 113-122, 1997.
3. Rooprai HK, Liyanage K, King A, Davies D, Martin K and Pilkington GJ: CD44 expression in human meningiomas: an immunocytochemical, immunohistochemical and flow cytometric analysis. *Int J Oncol* 14: 855-860, 1999.
4. Van Meter T, Rooprai HK, Kibble MM, Fillmore HL, Broaddus WC and Pilkington GJ: The role of matrix metalloproteinase genes in glioma invasion: co-dependent and interactive proteolysis. *J Neurooncol* 53: 213-235, 2001.
5. Pereda MP, Hopfner U, Pagotto U, Renner U, Uhl E, Arzt E, Missale C and Stalla GK: Retinoic acid stimulates meningioma cell adhesion to the extracellular matrix and inhibits invasion. *Br J Cancer* 81: 381-386, 1999.
6. Mizoue T, Kawamoto H, Arita K, Tominaga A and Kurisa K: Secretion of matrix metalloproteinase-9 and tissue inhibitor of metalloproteinase-1 by meningiomas detected by cell immunoblot analysis. *Acta Neurochir* 141: 481-486, 1999.
7. Nordqvist AC, Smurawa H and Mathiesen T: Expression of matrix metalloproteinases 2 and 9 in meningiomas associated with different degrees of brain invasiveness and edema. *J Neurosurg* 95: 839-844, 2001.
8. Kirches E, Grunewald J, von Bossanyi P, Szibor R, Plate I, Krüger S, Warich-Kirches M and Dietzmann K: Expression of matrix metalloproteinases in a series of 12 meningiomas. *Clin Neuropathol* 20: 26-30, 2001.
9. Nakagawa T, Kubota T, Kabuto M, Sato K, Kawano H, Hayakawa T and Okada Y: Production of matrix metalloproteinases and tissue inhibitor of metalloproteinases-1 by human brain tumors. *J Neurosurg* 81: 69-77, 1994.
10. Kachra Z, Beaulieu E, Delbecchi L, Mousseau N, Berthelet F, Moumdjian R, Del Maestro R and Béliveau R: Expression of matrix metalloproteinases and their inhibitors in human brain tumors. *Clin Exp Metastasis* 17: 555-566, 1999.
11. Hur JH, Park IC, Yi DH, Rhee CH, Hong SI and Lee SH: Matrix metalloproteinases in human gliomas: activation of matrix metalloproteinase-2 (MMP-2) may be correlated with membrane-type-1 matrix metalloproteinase (MT1-MMP) expression. *J Korean Med Sci* 15: 309-314, 2000.
12. Velasco G, Cal S, Merlos-Suárez A, Ferrando AA, Alvarez S, Nakano A, Arribas J and López-Otín C: Human MT6-matrix metalloproteinase: identification, progelatinase A activation, and expression in brain tumors. *Cancer Res* 60: 877-882, 2000.
13. Jäälinojä J, Herva R, Korpela M, Höyhty M and Turpeenniemi-Hujanen T: Matrix metalloproteinase 2 (MMP-2) immunoreactive protein is associated with poor grade and survival in brain neoplasms. *J Neurooncol* 46: 81-90, 2000.
14. Lilja A, Nordborg C, Brun A, Salford LG and Aman P: Expression of the IL-6 family cytokines in human brain tumors. *Int J Oncol* 19: 495-499, 2001.
15. Heussen C and Dowdle EB: Electrophoretic analysis of plasminogen activators in polyacrylamide gels containing dodecyl sulfate and copolymerised substrates. *Anal Biochem* 102: 196-202, 1980.
16. Rucklidge GJ, Lund-Johansen M, Milne G and Bjerkvig R: Isolation and characterization of a metalloproteinase secreted by rat glioma cells in serum-free culture. *Biochem Biophys Res Commun* 172: 544-550, 1990.